ISSN: 2519-7053 (Print)
ISSN: 2519-7878 (Online)

NJHS

National Journal of Health Sciences

Vol. 10, No. 4,

2025

Quarterly

- *Breakthrough Pharmacotherapy Redefining Obesity Management*
- *E-Cigarette Use Linked to Significant Oral Health Complications*
- *Critical Gaps in VTE Prophylaxis for Pregnant Women*

NiBD Publications

www.njhsciences.com

NJHS
National Journal of Health Sciences

Editorial Board

Editorial Team

Patron-in-Chief
Mr. Mohiuddin Chawla

Editor-in-Chief
Dr. Tabinda Ashfaq
MBBS, FCPS, FRCGP
Outreach Clinical Lead, Department of Family Medicine, The Aga Khan University, Karachi, Pakistan.

Editor
Dr. Tasneem Farzana
MBBS, MCPS, Dip Haem, FRCP (London)
National Institute of Blood Disease & Bone Marrow Transplantation, Lahore Campus, Pakistan.

Managing Editor
Muhammad Akif Ali Atif

Founding Editor-In-Chief
Dr. Tahir S. Shamsi (Late)
MBBS, MRCPath, FRCPath
National Institute of Blood Disease & Bone Marrow Transplantation, Karachi, Pakistan.

Advisory Board

Dr. Fatima Riaz
MBBS, FCPS (Family Medicine), MRCGP (International) Family Medicine
Department of Family & Community Medicine, College of Medicine, King Khalid University Abha, KSA

Dr. S.H. Waqar
MBBS, FCPS, MCPS-HPE, FACS, CME
PIMS and Federal Medical College, Islamabad, Pakistan.

Dr. Tabinda Ashfaq
MBBS, FCPS, FRCGP
Outreach Clinical Lead, Department of Family Medicine, The Aga Khan University, Karachi, Pakistan.

Dr. Tasneem Farzana
MBBS, MCPS, Dip Haem, FRCP (London)
National Institute of Blood Disease & Bone Marrow Transplantation, Lahore Campus, Pakistan.

National

Dr. Abdul Majeed Chaudhry
MBBS, FRCS, FCPS, MHPE, FCSSL, FASI
Lahore Medical & Dental College, Lahore, Pakistan.

Dr. Aizaz Mand Ahmad
MBBS, FCPS (Medicines), FCPS (Nephrology), FRCP (London)
Evercare Hospital Lahore, Pakistan.

Dr. Farid Ahmed
MBBS, FCPS, FRCS (UK)
Alrazi Health care, Surgimed Hospital, Lahore, Pakistan.

Dr. Nazish Saqlain
MBBS, FCPS (Haematology)
Postgraduate Medical Institute/ Ameer-ud-din Medical College/ Lahore General Hospital, Lahore, Pakistan.

Dr. Nazli Hossain
MBBS, FCPS (Obs & Gyne), MBE
Dow University of Health Sciences, Karachi, Pakistan.

Dr. Qamaruddin Baloch
MBBS, FCPS (Surgery)
Al-Tibn Medical College & Hospital Isra University Karachi Campus, Pakistan.

Dr. Rahat-Ul-Ain
MBBS, FCPS (Paeds), FCPS (Paeds/ Haem/Onco)
The Children's Hospital and Institute of Child Health, Lahore, Pakistan.

Dr. S.H. Waqar
MBBS, FCPS, MCPS-HPE, FACS, CME
PIMS and Federal Medical College, Islamabad, Pakistan.

Dr. Soufia Farrukh
F.C.P.S, F.R.C.S. (Glasgow)
Ophthalmology PGD & MSc (MED. EDU.)
Quaid-e-Azam Medical College, Bahawalpur, Pakistan.

International

Dr. Gulali Aktas
MD, PhD (Internal Medicine)
Department of Internal Medicine in Faculty of Medicine, Abant Izzet Baysal University, Golkoy, 14030, Bolu, Trkiye.

Dr. Mohiuddin Ahmed Khan
MBBS, FCPS (Hematology, BCPS, FRCP)
Department of Hematology, Dhaka Medical College Hospital, Dhaka, Bangladesh.

Dr. Muhammad Akram
M.D., M.B.A., F.A.C.C., F.S.C.A.I.(Cardiology)
Cardiac Center of Texas, USA.

Dr Najam Us Saqib
M.B., B.S., DA (Eng.), FCARCS (Ire.)
Doncaster & Bassetlaw NHS Foundation, Bassetlaw Hospital, United Kingdom.

Dr. Suleman Atique
PhD (Biomed. Informatics)
Department of Obstetrics and Gynecology, Oslo University Hospital (OUH), Rikshospitalet, Oslo, Norway.

Editorial Secretariat

Ms. Maria Baig
Editorial Manager

Published under No. DC/EAST/HVC/Leg Br.24/2016 for NIBD Publications and printed at KAGZI Printers, Karachi, Pakistan.

Plot # 16, Maqbool Society, Block 7-8, Lal Muhammad Chaudhry Road, Karachi 75350, Pakistan.
(92 21) 34392398 & 34392399, www.njhsciences.com

Note: ORCID® is a registered trademark and the ORCID logo and iD icon are trademarks of ORCID, Inc.

NJHS
National Journal of Health Sciences

About Us:

The National Journal of Health Sciences (NJHS) is the official publication of the National Institute of Blood Disease & Bone Marrow Transplantation (NIBD & BMT), Karachi, Pakistan. The journal serves as a dedicated platform for healthcare professionals, fostering the dissemination of substantial and credible contributions to the field of health sciences.

National Journal of Health Sciences publishes high-quality, peer-reviewed scholarly articles encompassing a wide range of research disciplines in both electronic and print formats. The journal offers an efficient and user-friendly submission system designed to facilitate a smooth and timely publication process. All submitted manuscripts undergo a rigorous double-blind peer review process, ensuring the highest standards of academic integrity and scientific excellence.

Each issue of National Journal of Health Sciences features clinically relevant and evidence-based research, readily accessible to the medical professionals, with the aim of advancing healthcare knowledge and fostering research development across the health sciences community.

Vision Statement:

The National Journal of Health Sciences is committed to driving trans-formative progress in healthcare by fostering interdisciplinary collaboration, advancing equity in scientific dialogue, and promoting excellence in research dissemination.

We envision a future where high-quality, evidence-based knowledge serves as the foundation for measurable improvements in patient outcomes, healthcare systems, and population health worldwide.

Mission Statement:

At National Journal of Health Sciences, our mission is to uphold the highest standards of ethical integrity and scholarly excellence in health sciences publishing. We provide an inclusive and dynamic platform for the dissemination of rigorously reviewed research, aligned with international best practices, including ICMJE, COPE, and EQUATOR guidelines.

Committed to fostering transparent scientific dialogue, we emphasize robust peer review, editorial integrity, and equitable access to knowledge. By championing innovation, diverse perspectives, and translational relevance, National Journal of Health Sciences empowers researchers and healthcare professionals to address critical health challenges and contribute to sustainable, evidence-based solutions that advance global healthcare.

Disclaimer:

The content published in the National Journal of Health Sciences (NJHS), including but not limited to research articles, reviews, editorials, perspectives, letters to the editor, case reports, short communication reflects the views and opinions of the individual authors and does not necessarily represent the official position or endorsement of National Journal of Health Sciences, its Publisher, Editorial Board, Editors, or Editorial Staff. Authors are solely responsible for the accuracy, integrity, and originality of their submitted and published work, including all data, analyses, interpretations, and conclusions. This responsibility extends to ensuring compliance with ethical guidelines, research standards, and applicable laws, including those related to copyright, intellectual property, and data privacy.

National Journal of Health Sciences, its Publisher, Editorial Board, Editors, and Editorial Staff disclaim any liability for:

Errors or omissions: We do not warrant the completeness or accuracy of the information published. **Consequences of use:** We shall not be held liable for any direct, indirect, incidental, consequential, or punitive damages arising from the use of or reliance on the content published in National Journal of Health Sciences. **Third-party content:** We are not responsible for the content of any external websites or resources linked to or referenced in the journal. **Ethical breaches:** Authors are responsible for ethical compliance, and National Journal of Health Sciences (NJHS) shall not be held liable for any ethical breaches committed by authors. **Legal liabilities:** We are not responsible for any legal issues that may arise from the publication of authors' content.

Authors warrant that their submissions are original, do not infringe upon the rights of others, and have not been previously published or are under consideration for publication elsewhere, except as disclosed in their submission. Authors agree to indemnify and hold harmless National Journal of Health Sciences, its Editorial Board, Editors, and Editorial Staff from any claims, liabilities, or expenses arising from their published work.

By submitting a manuscript to National Journal of Health Sciences, authors acknowledge that they have read, understood, and agreed to this disclaimer and its terms. This disclaimer is subject to change without notice.

NJHS
National Journal of Health Sciences

Table of Content
Volume 10, Issue 4, 2025

Editorial

220 Transforming Obesity Care: Medications at the Forefront

Tabinda Ashfaq

Research Articles

222 Association of E-Cigarette Use and Oral Health Complications: A Cross Sectional Study in Punjab, Pakistan

Muhammad Taaha, Naila Umer, Hafiz Danish Altaf, Rabia Anjum, Hammad Hassan, Safi Ullah Khan

230 Is Obesity Associated with a Higher Risk of Differentiated Thyroid Cancer in a Cytologically Proven Series of Thyroid Nodules?

Irfan Ahmed Shaikh, Danish Ur Rehman, Sidra Bano, Rajesh Kumar, Ramsha Khalid, Raheem Bakhsh

238 Diagnostic Accuracy of Ultrasound in Detecting Axillary Lymph Nodes in Patients with Early Breast Cancer Taking Histopathology as a Gold Standard

Ambreen Shaikh, Saleha Anwar, Hasnain Ali, Raisa Altaf Malik, Humaira Erum, Bisma Rizwan

244 Role of Heparin to Prevent Hypertrophic Scarring in Donor Area of Split Thickness Skin Graft

Asma Ishtiaq, Faisal Akhlaq Ali Khan, Farhan Zahid, Iqra Muhammad Tasleem, Asra Zahid, Nasreen Bano Khatri

251 Outcomes of Intestinal Anastomosis with or without Platelet Rich Plasma Application

Syeda Wajiha Mustafa, Malik Asad Munir, Atika Tahir, Batool Fatima, Muhammad Azam Mirza, Muhammad Kashif Bashir

258 Risk Assessment of Venous Thromboembolism in Pregnancy and Adequate Prophylaxis: An Observational Study

Aliya Nasim, Sagheera Anjum Manaver, Naima Shah, Humaira Tahir, Mehvish Kanval

264 Experience in Pediatric Bleeding Disorders in Tertiary Care Health Services from Southern Region of Saudi Arabia: Single Center Retrospective Study

Badriah Gharamah Al Asmari, Ali Mujtaba Tahir, Mohammed Alpakra, Mohaned Mustafa Ahmed Mohammad, Sara Saeed Mahamoud Hassanien, Mahnoor Saeed, Manea Abdullah Alqarni, Sami Saleh Alamri

271 Prevalence of Depression and Anxiety in Patients with Obstructive Lung Disease and Correlation with Spirometry

Ehab Nabeel, Sohail Akhtar, Ahmed Ali, Syed Wajahat Hussain, Mujahid Hussain

279 In-Hospital Outcomes of Early Extubation in Post CABG Patients: A Retrospective Study from a Tertiary Care Hospital in Karachi, Pakistan

Qaiser Aziz Khan, Latifa Haidari, Imran Khan Sandeelo, Marium Nastaeen Sarhandi, Sarib Bin Yasir, Mariam Amir

287 Knowledge, Attitudes & Perceptions towards Premenstrual Syndrome among Low Socioeconomic School-Going Adolescent Girls in Karachi, Pakistan

Shaikh Ali Masood, Shabbir Ahmed Mallick, Hamna Jamal, Maria Murtaza, Manahil Nadeem, Ameera Shabbir

292 Timing of Surgical Intervention and its Impact on Short-term Outcomes in Pediatric Hydrocephalus

Shakeel Ahmed, Shoaib Saleem Khan, Syed Zahid Hussain Shah, Muhammad Ali Waqas, Ubaid Ullah, Zeeshan Karim

Case Report

299 Spontaneous Resorption of Mandible in a Middle Aged Female

Hafiz Muhammad Bilal Siddiqui, Hafiz Murtaza Hussain, Talha Ahmed Qureshi, Mariam Mubashir

National Journal of Health Sciences, 2025, *10*, 299-303

Case Report

Spontaneous Resorption of Mandible in a Middle Aged Female

Hafiz Muhammad Bilal Siddiqui[1], Hafiz Murtaza Hussain[1], Talha Ahmed Qureshi[*,2], Mariam Mubashir[3]

[1]*Section of Otolaryngology, Department of Surgery, Patel Hospital, Karachi, Pakistan.*
[2]*Section of Otolaryngology, KIMSHealth Medical Center, Bur Dubai, United Arab Emirates.*
[3]*Department of ENT, Dow University of Health Sciences, Karachi, Pakistan.*

Abstract: Gorham's disease, also called vanishing bone disease or massive osteolysis, is a rare disease that is characterized by spontaneous and progressive osteolysis of one or more skeletal bones [1]. Until now, there are about 200 cases described in the literature. 41 (21.1%) of them are related to the maxillofacial region, specifically the mandible [2].

Keywords: Vanishing bone disease, Gorham's disease, Bone disorder, Progressive osteolysis, Humerus, Axial skeleton.

INTRODUCTION

Gorham's disease (GD), also known as phantom bone disease, progressive osteolysis, disappearing bone disease, vanishing bone disease, acute absorption of bone and idiopathic massive osteolysis, is a rare bone disorder in which one or more bones in an affected person are destroyed and resorbed spontaneously, progressively [3-4]. The specific etiology of this condition is still unknown and no metabolic or endocrinological association can be identified. The first case of Gorham's disease has been described by Jackson in 1838 and Romer described the case of the jaw of a 31-year-old female in 1924 [5, 6]. The disease was later established as a separate pathological process by Gorham and Gorham & Stout in 1954-55 [1, 7]. Gorham's disease may involve any bone in the body with predilection in the humerus, axial skeleton, pelvis and jaw (mandible, basal and alveolar bones followed by ramus and condyles) [1, 8]. This condition mostly affects people under 40 years of age including both males and females, and the clinical features of this condition depend on the site of affected bone [9, 10].

We present a case of middle aged female who was presented to our clinic with the complain of spontaneous left mandibular bone resorption.

The current study was performed in Patel Hospital, Karachi, Pakistan and approved by Ethics Committee (No. PH/IRB/2023/022). The patient's family gave informed written consent.

50 years old female patient no known co-morbidities, came with complain of left mandibular bone resorption and depression forming at angle of mandible (Fig. **1**.) along with pain and neck muscle stiffness since January 2023.

* Address correspondence to this author at the Section of Otolaryngology, KIMSHealth Medical Center, Bur Dubai, United Arab Emirates.
Email: tal_qureshi@yahoo.com

Fig (1). Depression at Angle of Left Mandible (A, B).

According to patient she accidentally noticed that there is a depression forming near her mandible bone and it continue to progress, followed by pain along with muscle stiffness along that specified region and neck, resulting in increased in pain intensity.

Patient also complains that she had also been experiencing burning and tingling sensation around left mandibular region. Patient took multiple medications from nearby clinic but pain didn't settled and condition continues to progress and deteriorate.

Patient also complains that she had been experiencing pain in various joints of body along with weakness.

On Examination, there was absence of angle of mandible on palpation on left side due to bone resorption and a depression created in that region. Intraoral examination was unremarkable, oral hygiene was poor, patient had dental carries, and there was absence of left upper molar and premolars. No tenderness or pain at left temporomandibular joint.

doi.org/10.21089/njhs.104.0299 © 2025 NIBD Publications

A full baseline workup was performed, including serum calcium, Vitamin D, parathyroid hormone (PTH), endocrine evaluation, and autoimmune profile, all of which were within normal limits. The patient did not report any generalized bone pain, joint pain, or backache at any time, and there were no clinical features suggesting systemic skeletal involvement. Therefore, a bone scan was not indicated at this stage, particularly given the detailed radiological evaluation already completed (OPG and CT), which localized the osteolysis to the left mandibular angle (Figs. **2**-**4**.)

Fig. (2). Osteolysis of Left Angle of Mandible (arrow).

Fig. (3). Biopsy being Done under General Anesthesia.

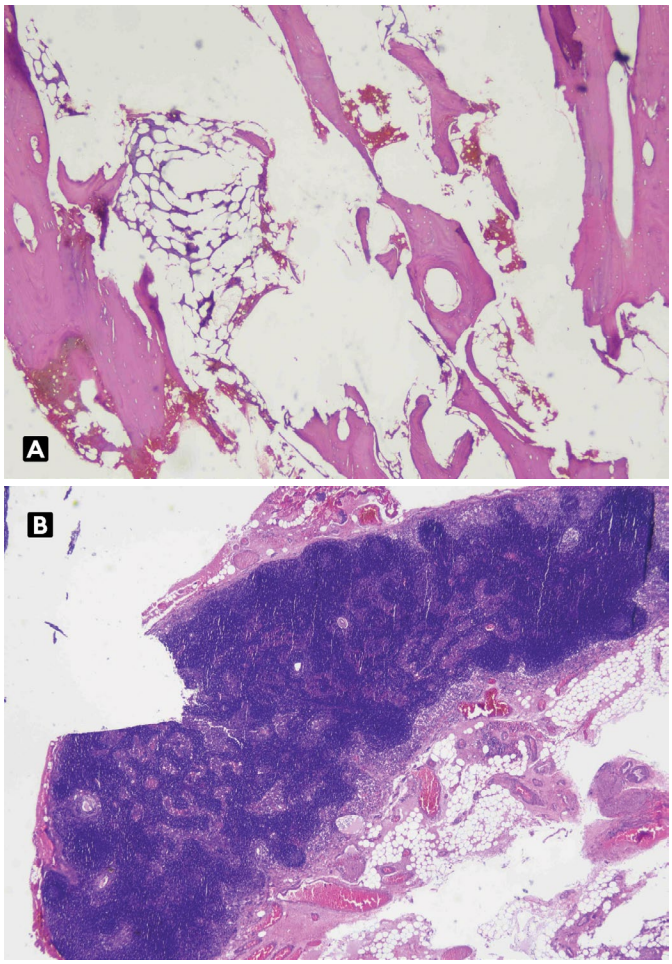

Fig. (4). (A) Fragments of mature cortical bone and marrow elements. Negative for inflammation, granuloma and malignancy. **(B)** Lymph node with intact architecture and no evidence of malignancy.

Regarding treatment and follow-up, the patient is being managed conservatively. She has been kept on regular outpatient follow-up visits, and her condition is monitored closely. She is currently on daily multivitamin and mineral supplementation. Family counselled in detail regarding management plan. Despite conservative measures, the osteolysis of the left mandibular angle continues to progress; therefore, the current management plan is surgical stabilization using plate fixation to preserve mandibular strength and prevent spontaneous fracture. Follow-up laboratory values, including Vitamin D, calcium, and PTH, have remained within normal limits throughout subsequent visits.

DISCUSSION

The mandible is the most common site of involvement from the reported cases of craniofacial tissue involvement from literature. According to Schiel and Prein, only 31 cases have been described involving maxillofacial presentation that satisfies the diagnostic criteria for massive osteolysis devised by Heffez *et al.*, [11, 12].

- Localized progressive osseous resorption.
- Little to no osteoblasts response, no dystrophic calcification.
- Lesion is non-expansile and non-ulcerative.
- No visceral participation Osteolytically appearance on the radiograph Negative results for hereditary, metabolic, neoplastic, immunologic or infectious origin.

Gorham's disease is aged by post-traumatic or taking place bone destruction connected to active bone hyperaemia. Between an early diagnosis and the disease itself It is hard to diagnose Gorham's disease, especially early on. It should be distinguished from multiple diseases such as osteomyelitis, trauma, hyperparathyroidism, malignancies and neurotic diseases [13]. Most of the cases occur in people under 40 though it can occur at any age (18 months to 72 years) [10]. Bone destruction usually progresses in a period of months to years, and may result in total bone losses. Some cases may arrest spontaneously without the total loss. Prognosis varies: slight disability to fatal outcome (16% mortality) [14]. Severe disability may occur if cervical spine, pelvis or thorax is involved. Peripheral bone disease allows long-term survival with more or less deformed [15, 16].

The difficulty in this osteolytic disease is both in its diagnosis and treatment [17]. Diagnosing GSD is difficult but requires good clinical suspicion along with diagnostic tests. Clinical evaluation is facilitated by blood test, X-ray, CT Scan, MRI etc. but histopathology gives definitive diagnosis [18].

During the early stages of the disease, there are no symptoms, and radiographs are typically used to identify the condition. Even nearby soft tissue may be invaded with bone tissue absorption, which is spontaneous and progressive until the entire bone is affected [19]. Patients with severe maxillofacial GSD may exhibit symptoms such as defective mouth opening, facial asymmetry, tooth movement, decreased occlusal function, pathological fracture, and others. Even when the patient has a history of toothaches, there may not always be an inflammatory reaction [20]. On the other hand, a quiescent phase, in which bone resorption is steady and does not advance, may be experienced by certain people with self-limiting osteoporosis [21].

The treatment approach for Gorham's disease is based on the condition of the individual patient, based on the severity of the disease and the location of involvement. According to what is known in the literature, bisphosphonates have been discussed as a possible option in the therapeutic approach to stabilize the process of bone resorption. A very interesting example is a case described by Hammer *et al.*, in which a 45-year-old male patient showed a stable clinical outcome after treatment with pamidronate given intravenously (IV) at a dose of 30 mg every 3 months for 2 years [22]. Radiological evidence obtained during the treatment period did not suggest any progression of bone destruction at the patient's ribs, leading to the suggestion that the treatment regime may have been responsible for stabilization of the destructive bone disease process.

Various treatment approaches have been explored in the treatment of Gorham's disease such as medical treatments including oestrogen, calcium, vitamin D, fluoride, bisphosphonates and calcitonin [23, 24]. Surgical options include excision, bone grafting and artificial implants [25, 26]. However, such treatments have had some limited success. Low-dose radiotherapy has been proposed to prevent the progression of osteolysis, however the use of radiation in this regards is controversial because of the risk, especially in children [27-29]. Watchful waiting and close monitoring is an option, particularly in pediatric cases [30]. For the said case, it's treatment planning including a bone graft and reconstruction using made-to-measure prosthetic devices.

CONCLUSION

This report documents a case of Gorham's disease arising in the mandible of a 50 years old woman. Essentially, the imaging characteristics include bone resorption without an associated soft tissue mass or other evidence of a neoplasm or any sign of inflammatory disease. Also the histopathology was unremarkable for inflammation, granuloma and malignancy. The aetiology and details of the disease mechanism remain controversial. Gorham's disease should be considered as a possible diagnosis when significant bone destruction occurs without an apparent cause.

LIST OF ABBREVIATIONS

GD: Gorham's Disease.

IV: Intravenously.

PTH: Parathyroid Hormone.

AUTHORS' CONTRIBUTION

Hafiz M. Bilal Siddiqui: Conceptualization.

Hafiz Murtaza Hussain: Methodology, Data analysis and interpretation.

Talha Ahmed Qureshi: Critical review and revision of the manuscript, Final approval, final proof to be published.

Mariam Mubashir: Writing draft.

ACKNOWLEDGEMENTS

Declared none.

ETHICAL DECLARATIONS

Data Availability Statement

Data will be available from the corresponding author upon a reasonable request.

Ethical Approval

The current study was performed in Patel Hospital Karachi Pakistan and approved by Ethics Committee (No. PH/IRB/2023/022).

Consent to Participate

The patient's family gave informed written consent.

Consent for Publication

Consented.

Conflict of Interest

Declared none.

Competing Interest/Funding

Declared none.

Use of AI-Assisted Technologies

The authors declare that no generative artificial intelligence (AI) or AI-assisted technologies were utilized in the writing of this manuscript, in the creation of images/graphics/tables/captions, or in any other aspect of its preparation.

REFERENCES

[1] Gorham L, Stout A. Massive osteolysis (acute spontaneous absorption of bone, disappearing bone): Its relation to hemangiomatosis. J Bone Joint Surg Am 1955; 37: 985-1004.

[2] Escande C, Schouman T, Francoise G, Haroche J, Me´nard P, Piette JC, *et al.* Histological features and management of a mandibular Gorham disease: A case report and review of maxillofacial cases in the literature. Oral Surg Oral Med Oral Pathol Oral Radiol Endod 2008; 106: e30-e7.

[3] Gondivkar SM, Gadbail AR. Gorham-Stout syndrome: A rare clinical entity and review of literature. Oral Surg Oral Med Oral Pathol Oral Radiol Endod 2010; 109: e41-8.

[4] Al-Jamali J, Glaum R, Kassem A, Voss PJ, Schmelzeisen R, Schön R. Gorham-Stout syndrome of the facial bones: A review of pathogenesis and treatment modalities and report of a case with a rare cutaneous manifestations. Oral Surg Oral Med Oral Pathol Oral Radiol 2012; 114: e23-9.

[5] Jackson JBS. A boneless arm. Boston Med Surg J 1838; 10: 368-69.

[6] Romer O. Die Pathologie der Zahne. In: von Henke F, Lubarsch O, Eds. Handbook of pathology, anatomy and histology. Berlin, Germany: Springer Verlag 1924; vol. 4: pp. 135-499.

[7] Gorham LW, Wright AW, Shultz HH, Maxon FC. Disappearing bones. A rare form of massive osteolysis: Report of two cases, one with autopsy findings. Am J Med 1954; 17: 674-82.

[8] Gondivkar SM, Gadbail AR. Gorham-Stout syndrome: a rare clinical entity and review of literature. Oral Surg Oral Med Oral Pathol Oral Radiol Endod 2010; 109: e41-8.

[9] Feng L, Wu Y, Yu X, Zhao W. Gorham's disease: Treatment with an autologous iliac bone graft and a reverse total shoulder arthroplasty. BMC Musculoskeletal Disord 2019; 20(1): 1-5.

[10] Tanoue N, Moedano L, Witte M, Montague M, Lukefahr A, Bernas M. Primary versus trauma-induced Gorham-Stout disease. Lymphology 2018; 51: 18-27.

[11] Schiel H, Prein J. Seven-year follow-up of vanishing bone disease in a 14-year-old girl. Head Neck 1993; 15: 352-6.

[12] Heffez L, Doku HC, Carter BL, Feeney JE. Perspectives on massive osteolysis: Report of a case and review of literature. Oral Surg Oral Med Oral Pathol 1983; 55: 331.

[13] Mohammad HK, Seyyed MH, Hossein B. Massive osteolysis of the mandible: A case report. J Oral Maxillofac Surg 2003; 61: 957-63.

[14] Ng SE, Wang YT. Gorham's syndrome with pleural effusion and colonic carcinoma. Singapore Med J 1995; 36: 102-4.

[15] Shives TC, Beebout JW, Unni KK. Massive osteolysis. Clin Orthop 1993; 294: 267-76.

[16] Kareem BA, Das PK, Saad R. Disappearing bone disease: A case report. Singapore Med J 1994; 35: 527-8.

[17] Ellati R, Attili A, Haddad H, Al-Hussaini M, Shehadeh A. Novel approach of treating Gorham-Stout disease in the humerus--Case report and review of literature. Eur Rev Med Pharmacol Sci 2016; 20: 426-32.

[18] Hyseni F, Vokshi V, Kola E, Fathma S, Guy A, Bushati F, *et al.* The importance of computed tomography (CT) scans in the early diagnosis of Gorham-Stout Disease–A case report. Radiol Case Rep 2022; 17(3): 492-5.

[19] Kai B, Ryan A, Munk PL, Dunlop P. Gorham disease of bone: Three cases and review of radiological features. Clin Radiol 2006; 61: 1058-64.

[20] Liu M, Liu W, Qiao C, Han B. Mandibular Gorham–Stout disease: A case report and literature review. Medicine 2017; 96(42): e8184.

[21] Zhao SF, Wang YX, Yang XD, Tang E-Y. Gorham disease of the mandible. J Craniofac Surg 2015; 26: e160-2.

[22] Hammer F, Kenn W, Wesselmann U, Hofbauer LC, Delling G, Allolio B, *et al.* Gorham- Gorham-Stout disease--stabilization during bisphosphonate treatment. J Bone Min Res 2005; 20: 350-3.

[23] Branco F, Da Horta JS. Notes on a rare case of essential osteolysis. J Bone Joint Surg Br 1958; 40: 519-27.

[24] Mendez AA, Keret D, Robertson W, MacEwen GD. Massive osteolysis of the femur (Gorham's disease): A case report and review of the literature. J Pediatr Orthop 1989; 9: 604-8.

[25] Ohya T, Shibata S, Takeda Y. Massive osteolysis of maxillofacial bones: Report of two cases. Oral Surg Oral Med Oral Pathol 1990; 70: 698-703.

[26] Booth DF, Burke CH. Massive osteolysis of the mandible: An attempt at reconstruction. J Oral Surg 1974; 32: 787-91.

[27] Handl-Zeller L, Hohenberg G. Radiotherapy of morbus Gorham-Stout: The biological value of low irradiation dose. Br J Radiol 1990; 63: 206-8.

[28] Dunbar SF, Rosenberg A, Mankin H, Rosenthal D, Suit HD. Gorham's massive osteolysis: The role of radiation therapy and a review of literature. Int J Radiat Oncol Biol Phys 1993; 26: 491-7.

[29] Ricalde P, Ord RA, Sun CC. Vanishing bone disease in a five year old: Report of a case and review of the literature. Int J Oral Maxillofac Surg 2003; 32: 222-6.

[30] Rauh G, Gross M. Disappearing bone disease (Gorham-stout disease): Report of a case with a follow-up of 48 years. Eur J Med Res.1997; 2: 425-7.

Received: August 08, 2025 Revised: December 04, 2025 Accepted: December 08, 2025

© 2025. The Authors, National Journal of Health Sciences.
This is an open access article distributed in accordance with the Creative Commons Attribution Non Commercial (CC BY- NC 4.0) license, which permits others to distribute, remix, adapt, build upon this work non- commercially, and license their derivative works on different terms, provided the original work is properly cited, appropriate credit is given, any changes made indicated, and the use is non-commercial. See: http://creativecommons.org/licenses/by-nc/4.0/.